



Cambridge 2023

ABSTRACT BOOK

Welcome to Cambridge



We look forward to welcoming you to the 23rd BAPES Congress in the beautiful university city of Cambridge.

With its famous 800 year old university, high-tech industries, beautiful gardens, vibrant art and drama scene, upmarket shopping, and amazing food and drink, Cambridge has much to offer.

You can go to the Fitzwilliam Museum or the famous Botanic gardens, take a punt down the river Cam, visit one of the many art galleries and restaurants in the city, or simply take a relaxing stroll through the city centre surrounded by magnificent old buildings of the University. Most of them are within walking distance of the Congress venue.

We have a dynamic and versatile department in the Cambridge University Hospital. We offer a full range of paediatric surgery and urology, and we are research active in clinical, as well as basic science.

The Congress will be held in the Møller Institute of Churchill College, a state of the art facility in Cambridge University. We have an excellent and varied two day programme, preceded by a MIS course that will be very useful for trainees at every level of experience.

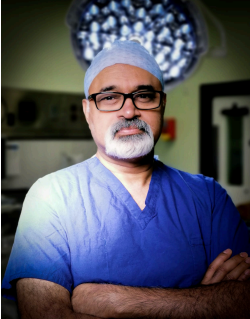
The conference dinner is being held in the Graduate Hotel on the banks of the river Cam. It will be a good opportunity to meet and socialize with old friends, and make new ones.

We hope you enjoy your stay in Cambridge, make most of the Congress and the city, and go back with fond memories.

Adil Aslam

Chair of the organising committee

From the president



Dear Colleagues

I am thrilled to be inviting you all to the 23rd Annual Scientific Meeting and Workshop of BAPES. This year we welcome you to the Møller Institute's state-of-the-art facilities at Churchill College in the University of Cambridge.

We have worked hard to provide a value-for-money opportunity to share experience, ideas, innovation and renew friendships in a warm and friendly atmosphere. Yet again our hands-on workshop is oversubscribed and has a great faculty using upper GI and pyeloplasty models.

The programme is packed with great abstracts and are looking forward to a productive time of discussion and debate. I am sure Our Meet the Expert session will go above and beyond on thoracoscopic lobectomy. We have two exciting guest lectures covering oesophageal replacement and robot-assisted surgery for neoplasms and malformations.

The annual dinner which we hope you will join will be at the Graduate Cambridge nestled on the banks of the river Cam.

We look forward to a time of refreshing and catching up. See you all very soon.

A handwritten signature in black ink that reads "Cherian". The signature is written in a cursive style and is underlined with two parallel lines.

Abraham Cherian
BAPES President

Thursday Nov 9th

14:10-14:55 Urology Papers Session 1

U1 CHARACTERISTICS OF PAPERS PRESENTED AT THE BAPES CONGRESS, 2019-2022

Esther Westwood, Alexander Macdonald. Chelsea and Westminster Hospital, London

Aims

To review characteristics of papers presented at the BAPES congress (focusing on sub-specialty and submitting centre) over a 4 year period.

Methods

Papers presented at the BAPES congresses 2019-2022 were identified from the publicly available congress programmes. Papers were grouped by sub-specialty and centre (UK-based (centre and consortium) vs international). Papers featuring robotics were noted as a separate group. Descriptive statistics were performed in Microsoft Excel.

Results

The total number of papers presented was 57 in 2019, 22 in 2020, 48 in 2021 and 41 in 2022. The most presented subspecialty was urology (57 papers, 34%). In 2019, upper GI had the largest share (30%); subsequently, urology has had the largest share (2020:45%, 2021:35%, 2022:41%). There were 6 robotics papers in 2019 and 3 in 2022 but none in the intervening years. 79% of papers were from UK centres. In 2019, 12% of papers were from international centres. This rose in 2020 (31%) but has since been decreasing (2021:27%, 2022:22%). Within the UK, the most represented consortium is London and the South-East (62% of UK papers). The most represented centres are Great Ormond Street (26, 20%) and Evelina (18, 14%).

Conclusions

Since 2020, urology has consistently been the most presented subspecialty. The majority of papers are from UK centres. Following an increase in 2020, the number of international papers is falling – this may be due to international centres wishing to attend local in person conferences. 34% of UK papers are from 2 centres in the London and South-East consortium.

U2 THULIUM FIBRE LASER (TFL) LITHOTRIPSY IN PAEDIATRIC UROLOGY

Mahmoud Abdelbary, Kevin Cao, Oliver Wiseman, May Bisharat. Addenbrooke's Hospital, Cambridge

Aim:

We share our experience with the Thulium laser fibre (TFL) for ureterorenoscopic lithotripsy with guided videos. We demonstrate cystoscopic access to the bladder, ureter and upper tract with stone dusting ensuring stone-free upper tract, featuring labelled audio guidance and insights.

Method:

Both of our presented cases had Extracorporeal Shock Wave Lithotripsy (ESWL) as an initial treatment performed as day cases.

Our first case involved a 14-year-old girl with bilateral small intra-calyceal calculi causing severe pain. Using the Thulium fibre laser endoscopic lithotripsy, nine calculi were disintegrated in under 30 minutes. The second case was a 5-year-old boy with a single 7 mm lower pole calculus. Access to the ureter was difficulty

in the first instance, so a JJ stent was left in situ for passive dilatation. On second attempt the calculus was successfully destroyed.

Results:

Following the application of the thulium laser, both patients were discharged in under 24 hours. In both instances, JJ stents were inserted. The second patient experienced self-resolving haematuria three days after the procedure. Follow up ultrasound at 3 months show that both patients were stone free.

Conclusion:

We hold the view that the thulium fibre laser (TFL) lithotripsy offers a comparable and likely superior stone free rate to the conventional Holmium yttrium-aluminium-garnet (Ho:YAG). The operative time and hospital stay have been markedly reduced. In this context, we are sharing insights through guided videos on our experience with this innovative technique. It holds promise in paediatric urology and could enhance modern stone management.

U3 URINARY LEAK FOLLOWING LAPAROSCOPIC PYELOPLASTY

Sugandh Chadha. Lakshmi Sundararajan, Heera T. Kanchi Kamakoti CHILDS Trust Hospital, Chennai, India

Aim

Urinary leak after pyeloplasty is reported in 2-5% after pyeloplasty. We report two children with urinary leak following laparoscopic pyeloplasty by transperitoneal and retroperitoneal approach to highlight increased morbidity of intraperitoneal urinary leaks

Method

Case report 1

3-year-old boy who underwent retroperitoneoscopic pyeloplasty with DJ stent insertion developed urinary leak from perinephric drain on POD-1. He was otherwise asymptomatic and leak settled following 48 hours of urethral catheter drainage. Total hospital stay was 3 days.

Case report 2

3-year-old girl with bilateral hydronephrosis R>L, underwent Cystoscopy/RGP showing Right PUJO with VUJO, requiring sequential surgery. On POD-2 after transperitoneal laparoscopic pyeloplasty with DJ stent insertion, child developed severe abdominal pain, distension with ileus, high grade fever and raised septic markers. X ray abdomen showed stent folded within the right ureter, USG abdomen showed perinephric urinoma. Cystoscopic Right VUJ stenting and laparoscopic drainage of urinoma was performed. Urine and peritoneal culture grew pseudomonas which was treated with antibiotics for 3 weeks. Leak stopped and drain removed after 4 days. Total hospital stay was 12 days. She underwent reimplantation after 4 months. Follow up USG/DTPA showed good resolution of hydronephrosis.

Conclusion :

The systemic consequences and morbidity of urinary leak is different in retroperitoneal vs. transperitoneal laparoscopic pyeloplasty. However, even after urinary leak, managed appropriately with antibiotics and adequate drainage of the system/collection, the pelviureteric anastomosis can heal well. This difference in morbidity should be weighed in the discussion regarding choice of transperitoneal and retroperitoneal approach for laparoscopic pyeloplasty

U4 RARE PRESENTATION OF PELVI-URETERIC JUNCTION OBSTRUCTION (PUJO) AFTER BLUNT RENAL TRAUMA AND ITS ENDOSCOPIC MANAGEMENT

Vanessa Coles, Khizer Mansoor, Hazem Mosa, Mark Lewis, Omar Al Kadhi, Azad Mathur. Norfolk and Norwich Hospital NHS Foundation Trust, Norwich

Aims

We present a rare case of renal collecting system rupture, associated with an incidental pelvi-ureteric junction obstruction (PUJO), secondary to blunt abdominal trauma.

Methods

A 13-year-old Boy presented with significant abdominal pain after falling off his bike. A CT abdomen-pelvis revealed a ruptured left renal collecting system and a large urinoma extending from the left subphrenic space down to the pelvis, on a background of presumed PUJO.

Cystoscopy and retrograde pyelogram confirmed the diagnosis. A joint approach with paediatric and adult urology, along with interventional radiology was performed. A 4.7fr left double J stent was inserted with sonographic and fluoroscopic confirmation of position within the collecting system.

Results

Urinoma reduced significantly in size after 24 hours. IV antibiotics and urinary catheter were maintained until haematuria resolved. DMSA scan was planned for six weeks post discharge to help plan further management (laparoscopic pyeloplasty versus laparoscopic nephrectomy).

Conclusion

Incidental findings of congenital renal anomalies following trauma are rare and may present a unique challenge to the urologist. A multi-disciplinary approach can help in these complex patients.

Conservative management of collecting system trauma in the presence of PUJO is unlikely to be successful. Minimally invasive management via endoscopic stenting is safe and effective.

U5 LAPAROSCOPIC STRATEGIES IN COMPLEX UPPER URINARY TRACT OBSTRUCTION

Kristina Dzhuma. Gunter De Win, Pankaj Mishra, Lorenzo Biassoni, Abraham Cherian. Great Ormond Street Hospital, London

Aims

We enumerate the various laparoscopic strategies to resolve upper urinary tract (UUT) obstruction in the context of variations in anatomy and report their outcomes.

Patients and methods

Retrospective review of primary laparoscopic UUT reconstructions performed between 05/2012 - 05/2021. Anomalies included: malrotated kidney (MRK), horseshoe kidney (HSK), duplex kidney (DK), pure intrarenal pelvis (IRP) and mid-ureteric stenosis (MUS). Success was defined by postoperative resolution of symptoms, improvement of anterior-posterior renal pelvic diameter (APD) on US and drainage on Mag3. Complications were categorised by Clavien-Dindo grading. Outcomes compared using the Student's t-test with $P < 0.05$ considered statistically significant.

Results

Of the 214 laparoscopic primary UUT reconstructions 37 (17.2%) were: 13-MRK, 12-HSK, 4-DK, 4-IRP and 3-MUS. Dismembered pyeloplasty: 8, pyeloplasty with renal sinus dissection: 8, neo-PUJ anastomosis: 8, primary ureterocalycostomy: 7, pyeloureterostomy: 2 and uretero-ureterostomy: 4. Median follow-up was 43-months (range 8–108) with a success rate of 94.5% (35/37). Complete resolution of symptoms - 20/21; improvement of hydronephrosis on US-35/37 (median pre-operative APD 27mm vs. median postoperative APD 8 mm) [$P < 0.001$]; improvement of drainage on diuretic renogram in 32/34 kidneys and stable/improved DRF in 34/35 kidneys (median preoperative DRF - 45% vs. median postoperative DRF - 47%) [$P > 0.05$]. Postoperative complications managed medically (II Clavien) included urinary tract infections – 2 (5%), stent-related symptoms in 2 (5%) and 1 (3%) umbilical port site collection. Recurrent pelvi-ureteric junction obstruction PUJO occurred in one patient (3%) requiring redo surgery (IIIb Clavien), renal stones in 1 (3%) which resolved with ESWL (IIIb Clavien) and in 1 (3%) patient with a HSK, there was complete loss of ipsilateral kidney function but was managed conservatively up to date (I Clavien).

Conclusion

Laparoscopic transperitoneal approach allows the prompt recognition of insitu anatomical variants. UUT obstruction in such settings calls for a variety of strategies with excellent outcomes.

U6 SINGLE CENTRE RESULTS FOLLOWING INTRODUCTION OF STAGED LAPAROSCOPIC TRACTION-ORCHIDOPEXY (SHEHATA TECHNIQUE)

David Colvin, Ahmed Mohamed, Alistair Dick, Brian MacCormack, Evelyn Ervine. The Royal Belfast Hospital for Sick Children, Belfast

Aims

With reported atrophy rates of 0-11%, the staged laparoscopic traction orchidopexy is a viable alternative to the Fowler-Stephens procedure for management of intra-abdominal testis. We present our results following introduction of the procedure in July 2022 as our departmental standard approach.

Methods

10 patients have undergone the two staged procedure, with the first stage performed at a median age of 16 months (IQR 14-44 months) and a median interval of 10 weeks (IQR 8-16 weeks) between procedures. 6 patients had a left sided intra-abdominal testis.

1 patient with Prune Belly syndrome had traction orchidopexy performed on the right, following atrophy of his left testis after Fowler-Stephens orchidopexy.

At second stage procedure all testis were passed into the scrotum through the abdominal wall medial to the inferior epigastric vessels.

Patients were then reviewed at 6 months post-second stage to assess testicular position and atrophy rate.

Results

To date 5 patients have been seen in outpatients at a median post-operative interval of 24 weeks (IQR 23-27 weeks). All have resulted in scrotal testis with no clinical evidence of atrophy.

1 patient had two successive suture failures, but had a successful second stage performed with an interval of 27 weeks, resulting in a scrotal testis.

Conclusions

Our results mirror the excellent success rates reported at other centres utilising the Shehata method. We plan to continue our prospective data collection and report our results.

T1 THORACOSCOPIC LUNG RESECTION FOR INFLAMMATORY PULMONARY CONDITIONS IN CHILDREN

Md Afikul Islam, Nick Lansdale, David Wilkinson, Robert Peters. Royal Manchester Children's Hospital, Manchester

Aim

Thoracoscopy is well established for congenital lung malformations but less well described in inflammatory conditions where surgery may be more challenging. We describe our experience of thoracoscopic lung resection for inflammatory pathologies.

Methods

All patients undergoing resectional surgery for inflammatory pathology by three sub-specialised surgeons were identified from prospective records. Data collected included: demographics, pulmonary pathology, operative technique, length of stay and complications. Data are presented as median (range).

Results

Six patients (five female) were included. Four had bronchiectasis (left lower lobe) and one tuberculosis (right middle lobe): all required lobectomy. One had right lower lobe segment six aspergilloma requiring segmental resection. Age at surgery was 9.5 years (6-11) and weight 31.95kg (18.8-55.4). All had lung isolation using double-lumen endobronchial tubes or bronchial blocker. A standardised anterior approach (Hansen/Petersen, Copenhagen) was used with small utility incision (allowing VATS approach and specimen retrieval) and two 5mm ports. Pulmonary artery and vein branches were divided between Hem-o-lock polymer clips. Endoscopic staplers divided the bronchus and large pulmonary veins. Ligasure was used to divide parenchyma.

One (tuberculosis) required thoracotomy due to dense fibrosis, precluding pulmonary artery identification. Operative time was 323 minutes (280-360). There were no major peri-operative complications. One patient had a prolonged pneumothorax due to chest drain malfunction. Follow-up duration was 10 months (1month 18days-38months 7days).

Conclusion

Thoracoscopic lung resection is feasible and safe for inflammatory conditions. Although technically more demanding than in congenital pathologies, as demonstrated by longer operative times: this can be aided by a hybrid VATS technique.

T2 SURGICAL MANAGEMENT OF SPONTANEOUS PNEUMOTHORAX IN CHILDREN

Victor Emordi, Adil Aslam. Addenbrooke's Hospital, Cambridge & Leeds Children's Hospital, Leeds

Aim: Surgical intervention for primary spontaneous pneumothorax (PSP) involves thoracoscopic bullectomy with or without adjunct procedures such as mechanical or chemical pleurodesis, aimed at preventing recurrence. We aimed to access our recurrence rate following thoracoscopic bullectomy and staple line coverage only in children.

Methods: We retrospectively reviewed all cases of children with PSP managed with thoracoscopic bullectomy in our institution between 2013 and 2021.

Results: 17 thoracoscopic bullectomies were performed on 10 patients during the period. Apart from coverage of the staple line with fibrin glue, no adjunct procedure was performed in the first instance. There were nine males and one female with a median age of 14 years (12-16 years). Median post-operative length of stay was two days (2-5 days). No immediate peri-operative complication was seen. There were 3 (18%) recurrences seen during a median follow-up duration 15 months (3- 48 months). The median time to developing recurrence was 10 months (1.5-15 months). All recurrent cases had thoracoscopic subtotal pleurectomy, and recovered uneventfully.

Conclusion: From our series, thoracoscopic bullectomy with staple line coverage alone appears to be a safe and effective option for children with PSP in the first instance, as it is associated with less morbidity and minimal hospital stay. We recommend subtotal pleurectomy for patients with recurrence.

T3 TO DRAIN OR NOT TO DRAIN? WHAT TO DO FOLLOWING THORACOSCOPIC BULLECTOMY AND PLEURECTOMY

Anna Harris, Giampiero Soccorso, Michael Singh. Birmingham Children's Hospital, Birmingham

Aims

To assess whether the use of chest drains in thoracoscopic bullectomy and pleurectomy (BP) for spontaneous pneumothorax is necessary. The impact on opiate use in those with and without drains is also examined.

Methods

A retrospective case note review was performed on all patients having a thoracoscopic BP between March 2018 to March 2022. Data was gathered on initial management, chest drain use, opiate use and complications. A Mann Whitney U was used to compare the two groups.

Results

Fifteen patients were identified and 19 BPs were performed between 2 surgeons. Of these, a chest drain (CD) was placed in 11 and no chest drain (NCD) in 9 cases. The median age for both groups was 15 years and the length of stay was 2 days for the CD group and 1 day if NCD ($p < 0.05$). There was a greater duration of patient-controlled analgesia usage in the CD group (46.5 hours vs 13 hours, $p < 0.05$) and a higher total dose of intravenous morphine or equivalent in the CD group (1.635mg/kg vs 0.34 mg/kg, $p < 0.05$). One patient who had a bilateral BP and did not have a chest drain developed a pyopneumothorax requiring further surgery on the asymptomatic side.

Conclusion

Provided an uncomplicated, unilateral thoracoscopic BP is expected, leaving a chest drain may not be necessary and may reduce length of stay and opiate use.

T4 SPECIFIC INDICATIONS OF MANAGEMENT WITH MINIMALLY INVASIVE, IN PEDIATRICS THORACO-ABDOMINAL TRAUMA: 2 CASES REPORT

Asbel Manuel Jacobo. Dr Sergio Adrián Trujillo Ponce, Dr Guillermo Yanowsky Reyes, Dr Jaime Orozco. PerezAntiguo Hospital Civil de Guadalajara "Fray Antonio Alcalde"

Aim. Minimally invasive surgery in traumatised paediatric patients has gained value in recent decades, and there are currently specific indications for its application.

Method

We present the experience in 2 traumatised pediatric patients, who underwent a minimally invasive approach with a favorable evolution.

Conclusions. The minimally invasive approach is feasible as long as there are specific and ideal indications, as well as the equipment and skills.

T5 LONG GAP OESOPHAGEAL ATRESIA AND OESOPHAGO-GASTRIC DUPLICATION

Segun Omoleye. Shailesh Patel, Niyi Ade-Ajayi. King's College Hospital, London

Background:

Oesophageal atresia (OA) is uncommonly associated with foregut duplication. We report a patient with long gap OA and delayed diagnosis of oesophago-gastric foregut duplication (OGFD).

Case presentation:

A newborn underwent gastrostomy for long gap OA. At 3 weeks he had successful thoracoscopic OA repair. Following balloon dilatations of oesophageal stricture, his gastrostomy was closed at 20 months. At 2.5 years, he was thriving on a varied diet.

At 4.5 years, he had overt GORD, failure to thrive, chest infections and a reflux index of 14% on pH study. Nissen fundoplication was proposed for treatment failure.

At laparoscopy, while mobilizing the greater gastric curve, a sizeable tubular cyst heading towards the hiatus was unexpectedly found. The cyst was excised (subsequent histology was consistent with gastric duplication) and fundoplication suspended to allow for cross sectional imaging which confirmed a large left thoracic cyst.

At a further procedure, a large tense, cyst, adherent to the left lower lung lobe, pericardium, diaphragm and posterior thoracic wall was confirmed. Subtotal resection and mucosectomy were carried out. Finally, completion of Nissen fundoplication was performed and he was discharged after satisfactory recovery.

Conclusions:

1. Awareness of this rare association between OA and OGFD should prompt early, appropriate imaging where symptoms are suggestive
2. Suspending surgical intervention in the face of significant, unexpected, intra-operative findings may enable the gathering of additional information to facilitate appropriate decision making and surgery

T6 STAPLER FAILURE AND RECURRENT PNEUMOTHORAX: A THORACOSCOPIC CASE REPORT

Segun Omoleye. Ancuta Muntean, Shailesh Patel, Niyi Ade-Ajayi. King's College Hospital, London

Background:

Lobar lung resections may be expedited by bronchial stapling. Small rib spaces limit suitable devices. We report stapler failure during lobectomy, management and outcome.

Case presentation:

2 year old boy underwent thoracoscopic left lower lobectomy for hybrid lung lesion. Two applications of a 5mm stapler failed to achieve closure of the left lower lobe bronchus. 4/0 prolene suture was utilized instead and air tightness to 40cm H₂O confirmed. Two chest drains inserted and satisfactory post-operative Cxray obtained.

Chest drains removed sequentially then routine pre discharge Cxray revealed unexpected left pneumothorax. Given intra-operative difficulties, he underwent thoracoscopy which excluded air leak. Chest drains were re-inserted via existing port site wounds.

Recurrent pneumothorax resulted in further thoracoscopy. At PEEP pressures to 42 cm H₂O no bronchial or parenchymal air leak demonstrated. This time pleurodesis was performed with re-insertion of chest drains through fresh wounds. His post-operative clinical course, chest drain removal and Cxray on this occasion were unremarkable. Root cause analysis; bedside chest drain management including the use of a novel underwater seal system and removal technique, were considered sub-optimal.

Conclusion:

1. Careful patient selection, stapler technique, staple line inspection and chest drain care facilitate safe lung resection
2. Stapler failure lowered the threshold for diagnostic thoracoscopy for post-operative pneumothorax in this case

Friday Nov 10th

09:00-09:29 **General Papers Session 1**

G2 REVIEW OF OUTCOMES IN CHILDREN UNDERGOING DIAGNOSTIC HERNIOSCOPY FOR CONTRALATERAL HERNIA DEFECTS

Sugandh Chadha, Senthil Ganesh Kamaraj; Namasivayam S. Kanchi Kamakoti CHILDS Trust Hospital, Chennai, India

Aim:

To describe the demographics, technique, and surgical outcome in children undergoing unilateral inguinal hernia repair to rule out contralateral patent processus vaginalis(PV) sac by means of diagnostic hernioscopy through ipsilateral defect

Methods:

A retrospective study was conducted between the years 2018-2023. Children who presented with unilateral inguinal hernia defects and underwent a concurrent hernioscopy by two independent paediatric surgeons at a tertiary care centre were included. The data was classified into demographics, surgical findings, presence of contralateral patent PV sac, and post-operative outcome

Results:

Our sample size included 73 children, 63 boys, and 11 girls with a median age of 5.5 years(2 months- 14 years). Right-sided defect was noted in 53 (73%) children. A patent PV sac on the asymptomatic side was noted in 15 children (19.5%) which included cases of inguinal hernia (8), hydrocele (4), UDT(1). This is similar to as described in the literature (20-22%). A false negative was made out in one of our patients where no defect was noted on hernioscopy but subsequently presented with inguinal hernia. Post-procedural intra abdominal sepsis was noted in another child. No long term complications were noted in our series.

Conclusion:

With proper technique and ideal selection criteria, hernioscopy proves to be a promising procedure that is safe and can be used as a diagnostic modality in children undergoing herniotomy to rule out the presence of a contralateral patent PV sac. It reduces the need for undergoing another procedure in view of the significant incidence of subsequent contralateral hernia

An operating video will be included in the presentation which will be a demonstration of the technique adopted to perform the procedure.

G3 ROBOTIC EXCISION OF A GIANT ABDOMINAL LYMPHATIC MALFORMATION – A VIDEO PRESENTATION

Michael Aworanti, Melania Matcovici, Naved Alizai. Leeds Childrens Hospital, Leeds

A 3-year-old girl presented with progressive abdominal distension. Ultrasound and MRI abdomen demonstrated a large multiseptated cyst, occupying most of the abdominal cavity. Ovaries were normal and the origin of the cyst was suspected to be from the mesentery. No solid component was demonstrated and tumour markers were normal.

Our operative video shows the MRI findings and a schematic diagram of port placements. 1.8L of straw coloured fluid was aspirated percutaneously under ultrasound guidance prior to the insertion of the ports. The video demonstrates our technique of using the da Vinci robotic system for assessing the anatomy and extent of the cyst and the dissection. The cyst was found to originate from the posterior abdomen in the lesser sac and had several smaller components, attached to the posterior wall of the stomach. The robotic approach allowed for good visualisation with minimal retraction and handling of the surrounding structures. Complete excision of all the cysts was achieved robotically and the child was discharged uneventfully after 48hours.

Conclusion

This video highlights the excellent views and intraoperative dexterity achievable with the da Vinci robot. Initial percutaneous drainage of the cyst facilitated port placements and is a useful tool to remember in cases where the lesion occupies most of the abdominal cavity.

G4 LAPAROSCOPIC APPROACH FOR MANAGEMENT OF OBSTRUCTING COLONIC DUPLICATION IN A NEWBORN

Chloe Roy, Jimmy Lam. Royal Hospital for Sick Children and Young People, Edinburgh

Enteric duplications are rare, though most commonly arise in the small bowel. Surgical management with resection is widely accepted due to risk of complications. Laparoscopic management is increasingly popular but the literature is limited to case reports and small case series, predominantly in older infants and children. We previously presented our experience with lap-assisted resection of intra-abdominal cysts in 3 patients, aged 1-8 years. Here we present a case of lap-assisted management of an obstructing caecal duplication cyst in a term neonate on D3 of life.

The male baby presented on D1 with bilious vomiting. He was opening bowels and otherwise clinically well. Upper GI contrast showed no evidence of malrotation. Ultrasound at the same time (routine in our centre) suggested a cystic structure in the right flank. Repeat ultrasound confirmed a 2.5cm likely duplication cyst with adjacent distended bowel loops.

Laparoscopy on D3 showed marked small bowel dilatation and free fluid. The cyst was identified within the caecum. The right colon was mobilised laparoscopically allowing the caecum to be externalised through the extended infra-umbilical port site. An additional cystic lesion was identified in the terminal ileum mesentery - thought to be either an additional duplication cyst or a Meckel's diverticulum. Limited right hemicolectomy including both lesions was performed with an end-to-end anastomosis.

No post-operative ventilatory support or opiates were required. Enteral feeding was commenced D2 post-operatively. He was fit for discharge D5 following surgery. Laparotomy was avoided by use of diagnostic laparoscopy following review of imaging. Histopathology is awaited.

G5 TRANS-UMBILICAL LAPAROSCOPIC-ASSISTED APPENDECTOMY A MINIMALLY INVASIVE METHOD, A RANDOMIZED CONTROLLED STUDY

Raed Al-Taher, Mohamad Abdullah, Basel Abdin; Awni Shuhait; Moataz Abbad; Yahya Alqudah; Duha Ateieh; Saja Matar.

Introduction:

Acute appendicitis is a prevalent pathology with perforation higher in pre-school children. Gold Standard management involves laparoscopic appendectomy (LA). Trans-umbilical laparoscopic-assisted appendectomy (TULAA) is a single-incision approach to grasp the appendix and perform extra-corporeal appendicectomy.

Materials and Methods:

A randomized clinical trial of TULAA versus LA was conducted at a tertiary centre in Jordan. Consecutive paediatric patients (age under 13 years) with non-complicated acute appendicitis, were eligible for participation. Data collected included; perioperative parameters, operative time, gas time, postoperative hospital stay, pathology, complications, pain, and cost.

Results:

Out of the 50 initially enrolled patients, 47 were included in the analysis (25 in TULAA group (53.2%), 22 in LA group (46.8%)), of which only 12% and 31% of patients had perforated appendicitis, in the TULAA group and LA group consecutively. No early intraoperative complications were observed. Post-operative complications were seen in 4.8% in the LA group and 4% in the TULAA group. Conversion to LA was required in 6.3% of TULAA cases. TULAA had significantly shorter operative time, lower gas flow, gas time, gas pressure levels, and more cases operated without gas compared to LA. Pain relief, diet resumption, and hospital stay did not significantly differ between the groups. The cosmetic outcome was slightly better in the TULAA group but not statistically significant.

Conclusion:

TULLA offers an alternative approach to LA for acute appendicitis and may be of benefit in resource poor institutions whilst maintaining the benefits of the minimally invasive approach. TULLA may be limited to non-complicated appendicitis only.

09:29-10:03 Thoracic Papers Session 2

T7 INVESTIGATION OF THE ROLE OF A DIGITAL TOOL IN THE PREOPERATIVE ASSESSMENT OF MAJOR LUNG THORACOSCOPIC RESECTORS

Sara Ugolini, Elisa Zolpi, Lorenzo Tofani, Antonino Morabito, Salvatore Fabio Chiarerà, Arnaud Bonnard. Wythenshaw Hospital, Manchester

T8 A CASE OF UNEXPECTED FINDINGS IN A CONGENITAL LUNG LESION: CT CONFUSION AND THORACOSCOPIC CHAOS

Reesha Ranat. Michael Singh. Birmingham Children's Hospital, Birmingham

Introduction:

Congenital lung lesions (CLL) are rare with a varied natural history, making the clinical decision and management process equivocal. Awareness of the potential presence of CLL-associated anatomical abnormalities is imperative for adapting operative strategy.

Clinical case:

A 1-year old male with an antenatal diagnosis of a microcystic congenital cystic adenomatous malformation was born at term, in good condition and required no support or inpatient neonatal care. Whilst awaiting a post-natal CT scan, he suffered recurrent respiratory tract infections. The CT suggested a large (5.5x6.8x6.7cm), bronchopulmonary sequestration with dual blood supply from the pulmonary artery and an anomalous vessel arising from the subdiaphragmatic aorta. A mediastinal para-aortic component that could represent a potential neoplastic process was also reported. Given these unusual findings the patient was listed for an urgent thoracoscopic resection. Intraoperatively, there was further anatomic confusion. The left hemithorax contained a membranous diaphragmatic duplication dividing the left hemithorax into two

discreet compartments and separated the upper and lower lung lobes. This was not evident on imaging. The lower compartment contained an extensive extrapulmonary sequestration attached to a compressed lower lobe. Consistent with the CT, a large transdiaphragmatic arterial supply was noted. This lesion was excised at the hilar attachment to the left lobe along with anterior mediastinal lesion.

Conclusion and learning points:

Pre-operative imaging is essential for surgical planning, but not always sensitive for unusual or complex anomalies. A thoracoscopic approach to CLL provides greater intraoperative visualization, making surgical assessment and strategy more readily adaptive.

T9 COMPLEX BRONCHOPULMONARY FOREGUT MALFORMATIONS: EXPERIENCE FROM A SINGLE CENTRE

Ashitha Unny, Giampiero Soccorso, Michael Singh. Birmingham Children's Hospital, Birmingham

Aim:

We report our experience with the clinical management of complex, peri-diaphragmatic bronchopulmonary foregut malformations (BPFM): multilobar, bilateral congenital lung malformations (CLM) associated to foregut (bronchogenic and enteric) duplication cysts and or congenital diaphragmatic herniation (CDH).

Materials and Methods:

Retrospective case notes review of all patients with complex BPFM presenting to a single tertiary centre between 1997 and 2023. Patient demographics, pre-operative symptoms, antenatal and postnatal investigations, surgical intervention, and overall outcome were reported.

Results:

Twenty- three patients had complex BPFM. Antenatally, 11 were diagnosed appropriately, 12 were thought to have only a single malformation. Postnatal management identified a total of 50 abnormalities. There were 14 patients with multiple CLM. Six patients had CLM and foregut duplication cysts (FDC), 2 patients had CLM, FDC and CDH and 1 patient had diaphragmatic duplication with large hybrid CLM. Twenty patients underwent 26 operations: 2 CDH repairs and resection of 37 lesions demonstrating 9 histologically distinct BPFM.

Eighteen (90%) patients underwent single-stage surgical management. Minimally invasive lung-sparing segmental CLM resection and FDC excision were achieved in 17 (85%) patients. There were no major complications. The average length of stay was 5.5 days (range 3 – 14). No patients required readmission at 30-day.

Conclusion:

This is the first case series of the surgical management of complex BPFM. Single-stage minimally invasive lung-sparing segmental resection is effective and safe in complex BPFM.

T10 OUTCOMES FOLLOWING THORACOSCOPIC RESECTION FOR CONGENITAL LUNG MALFORMATIONS

Segun Omoleye, Ancuta Muntean, Akash Deep, Omar Hussain, Shailesh Patel, Niyi Ade-Ajayi. King's College Hospital, London

Aim:

A multi-disciplinary team has evolved to manage children with congenital lung malformation (CLM). We report outcomes following elective resectional lung surgery

Method:

Retrospective review (January 2013-December 2022); single lung ventilation (SLV) became default technique mid-way. The standardized pathway included post-operative HDU. Demographic data, details at surgery, critical care requirements and complications were recorded. Except stated, data are reported as median (IQR).

Results:

72 children (f/m=36/36) aged 12 (9-17) months weighing 10 (9-11.8) kg underwent surgery. Antenatal diagnosis; 70 (97.2%). CLM was left sided in 42 (58.3%); left-lower (n=25), upper (n=9), lingular (n=2) and sequestration (n=6). Pre-COVID years the mean number of patients 8.5/year compared with 4/year peri and post-COVID.

Anaesthetic time was 61 (15-168) minutes. 12 (16.6%) cases were converted to thoracotomy. Fifteen (20.8%) had blood transfusion for blood loss or SLV optimisation. The operative time was 229 (154-354) minutes. The majority required less than 24 hours on HDU and hospital stay was 4 (3-6) days. Significant complications; persistent air leak (n=1), haemorrhage (n=1) and pneumonia (n=1), pleural effusion (n=1).

Conclusions:

1. We report a large single centre experience of CLM resection
2. Post-operative critical care support was minimal and may not be routinely required
3. Reduction in post-COVID operation numbers may mean future surgery at an older age for children who spend longer on the waiting list
4. Given critical care bed constraints, particularly winter, post-operative general surgical ward management with critical care outreach support may be feasible and practical

T11 A RARE CONDITION PRESENTING AS A NON-RESOLVING PNEUMONIA AND PARA-NEOPLASTIC SYMPTOMS

Anna Harris, Michael Singh. Birmingham Children's Hospital, Birmingham

Aims

To present a rare case of an inflammatory myofibroblastic tumour of the lung presenting as a non-resolving round pneumonia with systemic symptoms.

Methods

A retrospective review of the notes was performed.

Results

A two year old girl presented with a 5 week history of malaise, cough, intermittent fever and limp. A chest x-ray showed a right lower zone round lesion. She had a microcytic anaemia, neutrophilia and raised CRP. She was started on intravenous antibiotics for presumed round pneumonia, which did not improve her symptoms. A CT scan showed a 3.5 x 4cm round, well demarcated lesion in the right lower lobe.

Due to the paraneoplastic symptoms, a whole body MRI with STIR was done. This showed periostitis of the long bones and small knee effusions. After discussion at the thoracic multi-disciplinary team meeting (MDT), a diagnosis of inflammatory myofibroblastic tumour of the lung was suggested. An anatomical, thoracoscopic segmentectomy was done and the diagnosis was confirmed on histology. ALK was negative. Post-operatively she recovered well and was discharged 4 days later. Her symptoms resolved over 3 weeks.

Conclusion

Inflammatory myofibroblastic tumours are benign tumours that are rare. They present with systemic symptoms and vague respiratory symptoms. It can be easy to assume they are infective and delay resection. If symptoms are not resolving with antibiotics, then consider further imaging and resection.

10:03-10:45 Urology Papers Session 2

U7 SURVEY OF PAEDIATRIC LAPAROSCOPIC ERGONOMICS IN INDIA

Sugandh Chadha, Lakshmi Sundararajan, Kanchi Kamakoti CHILDS Trust Hospital, Chennai, India

Aim:

To assess the awareness and identify the issues faced by paediatric surgeons in India in terms of Laparoscopic ergonomics.

Methods:

An online survey was done from July to August 2023 regarding laparoscopic ergonomics. Participants included junior and senior paediatric surgical trainees along with junior and senior-level paediatric surgical consultants working in India. The questions included gender, height, experience, complexity of procedure performed, preference of position of the monitor, operating table, length of instruments used and issues faced due to bad ergonomics.

Results:

The survey was filled by 151 paediatric surgeons with 119 males and 32 females working at teaching institutions (62%). Forty-eight percent of participants were senior consultants with > 10 years of experience. 79(52%) performed advanced laparoscopic procedures. Neonatal surgeries (71%) were the most challenging. Fifty-four (36%) surgeons faced musculoskeletal illnesses resulting from poor ergonomics. This was prevalent among senior consultants (31) males (38) surgeons with heights between 155-175cm (33), and aged between 35-50 years (27) performing advanced procedures (32). Most participants (149) were keen on improving their laparoscopic ergonomics. 140 (93%) surgeons noted that laparoscopic ergonomics was not given due importance at their hospitals and 84 (56%) lacked institutional support for acquiring the necessary infrastructure.

Conclusion:

We conclude that 36% of surgeons experienced musculoskeletal disorders while performing advanced procedures (32/54) ranging from fatigue, pains, and neuropraxia, and 40% of surgeons were oblivious towards preventive strategies. 93% of respondents reported that laparoscopic ergonomics was disregarded at work, and 56% said that management did not support them in getting the necessary infrastructure.

U8 SUCCESSFUL ENDOSCOPIC MANAGEMENT OF AN UNUSUAL BLADDER FOREIGN BODY

Dina Fouad, Chloe Roy, Julian Keanie, Jimmy Lam. Royal Hospital for Sick Children and Young People, Edinburgh

Aims:

To report an unusual case of a bladder foreign body which led to pyonephrosis and a distal ureteric stricture all of which was successfully managed endoscopically.

Methods:

Retrospective case note review.

Results:

A 10 year old female presented with signs of urinary sepsis, flank pain and haematuria. She was found to have inserted a metal coat hanger hook via her urethra into her bladder. This led to a left distal ureteric obstruction and left pyelonephritis with a pyonephrosis. A nephrostomy was inserted and successful cystoscopic removal of the coat hanger was completed with a wire stone retrieval basket device. 11 days later a JJ ureteric stent was able to be placed across a left distal ureteric stricture and the nephrostomy removed. 2 months later, ureteroscopy with retrograde ureterogram revealed an ongoing stricture and the JJ ureteric stent was replaced. 2 months following this, ureteroscopy and balloon dilatation of the distal ureteric stricture was performed. A follow up cystoscopic ureterogram 3 months following this confirmed no residual distal ureteric stricture. DMSA scan 8 months post injury showed a split function of 37% left and 63% right. She has remained asymptomatic with satisfactory imaging in over 2 year of follow up.

Conclusions:

A complex bladder foreign body and associated traumatic distal ureteric stricture was successfully managed endoscopically.

U9 FACTORS INFLUENCING SUCCESS IN ENDOSCOPIC TREATMENT OF HIGH-GRADE PRIMARY VESICO-URETERIC REFLUX (VUR)

Sonia Tiboni, Nisha Rahman, Diane De Caluwe, Marie-Klaire Farrugia. Chelsea and Westminster Hospital, London

Aims

To assess our outcomes of endoscopic Deflux in children with primary Grade 4-5 VUR. Primary outcome was recurrence of febrile culture positive urinary tract infections (UTI), secondary outcome was no further surgical intervention.

Methods

Single centre experience spanning 15 years. Retrospective review of a prospective VUR patient database. Patients with secondary VUR (obstruction, neuropathy, bladder bowel dysfunction) were excluded. Indication for intervention was breakthrough UTI or severe urosepsis presentation in infancy. Deflux injection was our first-line procedure in all cases (excluding ectopic ureters, obstructing megaureters or poorly functioning kidney). Data was analysed using Fisher's Exact Test.

Results

49 patients from a total of 77 with primary G4-5 VUR underwent a Deflux STING and/or HIT procedure. Median age at first intervention was 12 (3-84) months. Median follow up was 31 (2-144) months. Unless anaesthetic reasons warranted inpatient stay, all children had a day-case procedure. There were no complications/30 day readmissions.

16/49 patients had a further UTI but only 8/49 required further intervention. Repeat Deflux (7), ureteric reimplantation (1). There was no significant difference in outcome between antenatal vs postnatal presentation, duplex vs simplex or infant vs child. Boys do better than girls with 96% vs 72% ($p < 0.05$) requiring no further intervention. We routinely offer circumcision at time of Deflux (uptake 17/24 boys).

Conclusions

Our data assists with accurate counselling. Within small number limitations it shows endoscopic treatment is safe, has an 84% success rate, and is a first line option for all ages, genders and in duplex systems.

U10 LAPAROSCOPIC MITROFANOFF APPENDICOVESICOSTOMY - THE SOUTHAMPTON EXPERIENCE

Niall Kelly, Ewan Brownlee. Southampton Children's Hospital, Southampton

The Mitrofanoff appendicovesicostomy, and the related Yang-Monti ileovesicostomy, as continents catheterisable channels were important milestones in the management of neuropathic bladders. The operative technique of laparoscopic appendicovesicostomy was first reported over 30 years ago yet remains an infrequently performed procedure. The technique was recently introduced at our centre and we present the initial outcomes to date.

We retrospectively reviewed all appendicovesicostomy and ileovesicostomy procedures performed between June 2019 and July 2023.

12 cases were performed, including 4 that had concomitant bladder augmentation. Excluding patients with augments, 7 laparoscopic appendicovesicostomies and 1 laparoscopic-assisted ileovesicostomy were performed on 5 males and 3 females, with a mean age of 12.9y and mean BMI of 24.7 kg/m². All were performed with a view to helping manage long term continence. Operation time ranged from 2.4 to 13.1 hours, with all appendicovesicostomies completed entirely intracorporeally. Blood loss was minimal for all cases. Median length of stay was 5 days, ranging from 2 to 13 days. Minor complications were common but only a single case required an early operative intervention for complication. With a median follow up of 24 months, all patients were successfully catheterising via their mitrofanoff channels.

The laparoscopic Mitrofanoff appendicovesicostomy has been successfully introduced in our centre without significant complications and is now the standard method of Mitrofanoff where feasible.

U11 ECIRS – BEST APPROACH IN OBSTRUCTED REIMPLANTS (VIRTUAL)

Vidhya Tamizhvanan, Tirumalai Ganesan, Sripathi Venkat. Apollo Children's Hospital, Chennai, India

Background

Endoscopic Combined Intrarenal Surgery (ECIRS) is a procedure developed to deal with complex urolithiasis in adults. This combined upper tract and lower tract approach enables access to the entire urinary system in one sitting. We have in this paper shown its utility in two children with ureteral obstruction following trans-trigonal reimplantation.

AIM

We aim to show that ECIRS is a good endoscopic approach to decide 1. the level of obstruction in the ureter (post surgery) and 2. to carry out a temporizing procedure like stenting.

METHOD

Between 2020-2021 two children presented with ureteral dilatation following reimplantation. In both cases interventional radiology and retrograde endoscopic approaches failed. The case summaries are as follows:

Child 1- A two and a half year old male underwent tapering and trans-trigonal reimplantation for an obstructed megaureter. At 4 years of age gross ureteral dilatation with drop in renal function of >10% was noted. The interventional radiologist attempted antegrade stenting but failed due to severe ureteral tortuosity. A decompressive nephrostomy was done and using the ECIRS approach the ureter was scoped and the obstructed reimplant was stented. Follow-up showed partial recovery of function.

Child 2- An eighteen month old male underwent pneumovesicoscopic reimplant for bilateral VUR. He presented a year later with gross hydronephrosis and a drop in renal function or more than 10%. ECIRS enabled identification of the obstruction and stenting of the stenotic segment in one sitting.

RESULT

Though successful stenting of the intravesical ureter was achieved in both children, a redo procedure was needed. In both cases a ureterovesicostomy and extravesical reimplant was done (without reopening the bladder). Partial recovery of lost renal function was documented in both cases.

CONCLUSION

ECIRS using the Galdako-Valdivia position enables complete access the upper and lower renal tract in one sitting. Calyceal puncture enables the entire ureter to be accessed by the ureteroscope while combined cystoscopy enable access to the bladder and the ureteral orifice. ECIRS not only provides an answer to the question – where is the ureter obstructed?? But also enables DJ stent insertion. This approach is invaluable in situations of ureteral obstruction following reimplantation.

U12 ROBOTIC URETERO-URETEROSOTOMY IN CHILDREN- DISMEMBERED AND IN-SITU REPAIR: POINT OF TECHNIQUE (VIRTUAL)

Vidhya Tamizhvanan, Rajiv. P, Sripathi Venkat. Apollo Children's Hospital, Chennai, India

Aim

To demonstrate the utility of Robotic Uretero-Ureterostomy (RUU) by 2 different techniques in children with mid ureteric stenosis.

Method

In our unit between 2016-2023, forty-five children underwent robot assisted laparoscopic ureteral surgeries. Two children with mid ureteral narrowing (web and stenosis) and who underwent robotic correction are the subject of this paper.

Child 1- A 4 year old with a congenital valve just above the iliac vessel crossing, underwent a dismembered uretero-ureterostomy and has shown resolution of hydronephrosis and preservation of renal function on follow up.

Child 2- A 6 year old with urinary infection, and a mid ureteric narrowing (congenital stenosis) underwent an in-situ repair using the Hienke-Mikulicz's principle in view of the precarious blood supply . Follow-up has shown resolution of hydronephrosis and maintenance of renal function.

Results

Mean console time was 90min, oral resumption 3 hrs postop, hospital stay 3 days. There were no intraop or post complications, mean follow up of 3.6yrs. In both the children resolution of hydronephrosis and preserved renal function documented.

Conclusion

In this video presentation we aim to show dismembered and in-continuity uretero-ureterostomy as techniques for dealing with mid and lower ureteral narrowing in children. The blood supply of the ureter in these regions is precarious and the technique is tailored to maintain a robust supply to both ends thereby resulting in excellent healing without stricture formation.

11:45-12:46 General Papers Session 2

G6 THAT'S A WRAP: A SEVEN YEAR CASE SERIES OF PAEDIATRIC FUNDOPLICATION

Mahmoud Abdelbary, Aleksandra Berezowska, Kevin Cao, Wajid Jawaid, Adil Aslam. Addenbrooke's Hospital, Cambridge

AIM:

In this seven-year single surgeon case series, we describe how we managed paediatric gastro-oesophageal reflux disease (GORD) and the laparoscopic Nissen's fundoplication.

METHODS:

Retrospectively, data from all laparoscopic Nissen's fundoplication cases between 2014 and 2021 were compiled. Our surgical approach included technical considerations such as restrained diaphragmatic hiatus dissection with a lax gastric wrap. We collected patient demographics, perioperative details and outcomes for analysis.

RESULTS:

43 fundoplications were performed, six with concurrent gastrostomy insertion and three with gastrostomy replacement. Operative time reduced from 121 minutes in the first 10 to 99 minutes in the latest 10 cases, indicating a learning curve. Six cases (13.9%) were converted to open fundoplication due to dense para-oesophageal adhesions.

Three patients (6.9%) required redo surgery (two for tight wrap, one for wrap failure). Symptom resolution occurred in 27 patients (62.8%) with surgery alone, two post-dilatation (one for tight wrap, one for stricture) and 14 (32.6%) improving with additional medical therapy including erythromycin and alimemazine. 10 patients had concurrent neurological diagnoses, with three experiencing retching post-surgery. Five of these patients improved with surgery, four with medication and one patient after redo-surgery.

CONCLUSION:

Our series highlights 7 years of experience with GORD surgery, with progression evident in shortening operative times, symptom-resolution was achieved in more than two-thirds of patients with surgery alone. We share this clinical journey, with media supplements, offering learning points for aspiring minimally-invasive surgeons. These insights lay the groundwork for the next generation, dedicated to improving the lives of children with GORD.

G7 SUCCESSFUL LAPAROSCOPIC MANAGEMENT OF A TYPE 3 HIATUS HERNIA WITH ORGANO-AXIAL VOLVULUS

Juju Kurian, Ashok Rijhwani, Ashok Ram. Norfolk and Norwich University Hospital, Norwich

Operative video

This is a 4 year old girl who has had recurrent episodes of cough and vomiting which was occasionally blood stained, and iron deficiency anaemia since she was 6 months of age. This was initially attributed to milk and food allergy and later to ulcerative oesophagitis.

Persistence of symptoms despite medical measures entailed further investigations which revealed a hiatus hernia. At surgery we encountered a type 3 hiatus hernia with an organo-axial volvulus of the stomach. The stomach was fully in the chest and was densely adherent to the hernial sac. After taking down the adhesions and releasing the stomach, the sac was excised and the stomach returned back to the abdomen. This was followed by crural approximation and a floppy Nissen's fundoplication.

Following surgery, she made an uneventful recovery and at 6 month follow up is symptom free and growing well, with repeat investigations showing normal lungs and the stomach in the abdomen.

G8 CONSULTANT TO CONSULTANT MENTORING IN LAP SPLENECTOMY – LENGTHENING THE UMBILICAL

Dhanya Mullassery, Joe Curry. Great Ormond Street Hospital, London

Aim

Acquisition of advanced laparoscopic skills rarely happens before CCT and is the challenge of the new consultant. Attainment of performance is based on the development of technical skill, judgment and the relationship between the learner and mentor. Here we describe the process of transition from novice to new independence within the space of 11 laparoscopic splenic procedures.

Methods

Data was obtained from the medical files of 11 patients operated on for splenic procedures by the learner and mentor between 2019 and 2023. The operative pathway for the procedure was analysed and compartmentalised to provide focus for the process of development of operative skill. These steps included

- 1 Knowledge of lit, set up and port positioning
- 2 Isolation of spleen from all accessory vasculature and other structures
- 3 Isolation and division of the splenic hilum
- 4 Acquisition of the spleen for removal

Results

11 procedures were analysed. There were 5 females. The median age at the time of procedures was 7 (range 2-14). All procedures were completed successfully without need for conversion. All procedures were discussed between the mentor and learner prior and fully debriefed after. The learner made progress quickly and for the penultimate case needed support for the part 3 of the procedure. The last procedure was performed with the mentor unscrubbed.

Conclusion

Advanced laparoscopic procedures can be learned quickly and safely in a carefully controlled arena. The working relationship between learner and mentor is key as is the need for structure for the brief and debrief.

G9 ROBOTIC CHOLECYSTECTOMIES IN CHILDREN: A TRAINING MODEL.

Melissa Bautista, Sarah Vecchione, Melania Matcovici, Michael Dawrant, Naved Alizai. Leeds Children's Hospital, Leeds

Background

Cholecystectomy is a relatively uncommon procedure in children. The senior author started performing robotic cholecystectomy in 2006. Over the recent years robotic cholecystectomy is used as a training procedure for the HPB team.

Methods

We conducted a retrospective analysis of all consecutive cholecystectomies performed in our centre between January 2019 and January 2023. Case notes and operative notes were examined, and the relevant data extracted. Evidence of procedure complications, robot related technical complications, readmissions and contact with medical teams were collected. Where relevant, mean, median with ranges were calculated.

Results

25 robotic cholecystectomies were performed over the 4-year period, 16 of these by surgeons in training. 60% (n=15) in females, 68% (n=17) for idiopathic gallstones. Histology suggested cholelithiasis in 96% of cases (n=24). Haematological disorders were an underlying cause in 24% (n=6) cases. The median ASA grade was 2, and co-morbidities included obesity, haematological disorders, and ex-prematurity with previous abdominal surgery. The average length of the procedure was 140 minutes (range 60 -240 mins) with 0% conversion to open. There were no returns to theatre, with a median Clavien-Dindo classification of 0 (range 0-3). The most common post-operative experience was nausea, vomiting and pain requiring medications. The median length of stay was 1 day (range 1-6 days), with a 4% readmission rate (n=1).

Conclusion

The safety of Robotic cholecystectomy is comparable to laparoscopic cholecystectomy. We did not see an increased rate of complications when the procedure was used for training junior consultants and trainees.

G10 DAY CASE CHOLECYSTECTOMY IN CHILDREN – A PILOT CASE

Melissa Bautista, Sarah Vecchione, Melania Matcovici, Michael Dawrant, Dan Gilpin, Adam Peckham-Cooper, Naveed Alizai. Leeds Children's Hospital, Leeds

Background

Cholecystectomies are routinely performed as a day case procedure in adult practice. Routine day case cholecystectomies in children are yet to be established in the UK.

Methods

A literature review was conducted to assess the current practises. Advice was taken from our local adult services.

With adaptation of adult protocols and evidence from the current literature the authors developed a protocol to allow for day case procedures. The protocol focuses on patient selection criteria and guidelines for the pre, intra and post-operative care to enhance the success of same day discharge.

Results

The literature review demonstrated safety in rapid discharge of patients with few readmissions and complications. Literature on true same day discharge remains limited.

The pilot case was a 16-year-old with idiopathic gallstones and recurrent episodes of biliary colic. Day case option was suggested to the family in the clinic, who were keen to try.

The patient was admitted to the day case unit and underwent robotic cholecystectomy uneventfully. The protocol was followed. Oral intake and mobilization were established immediately postoperatively, as for any other day case. There were no immediate or intermediate complications to require overnight stay or a re-admission. A telephone assessment performed on day 5 post-op suggested good pain control and return to normal daily routine after two days.

Conclusion

Pre-operative preparation of the patient and following an established day case unit based protocol can be introduced successfully for day case minimally invasive cholecystectomies in children.

G11 NOT YOUR STANDARD LAP CHOLE...

Rania Kronfli, Mark Davenport. King's College Hospital, London

Operative Video

G12 BOTRYOID RHABDOMYOSARCOMA ARISING IN CHOLEDOCHAL MALFORMATION: A CASE REPORT, LESSONS LEARNT AND LITERATURE REVIEW

Sarah Vecchione, Johnson Rhys, Matcovici Melania, Dawrant Michael, Alizai Naved. Leeds Children's Hospital, Leeds

Aims:

Left untreated, malignant change is a well-recognised risk of choledochal malformation (CM). Most common type of cancer reported is rhabdomyosarcoma (RMS). In children RMS has been reported as a primary malignancy that can cause biliary obstruction, mimicking CM. There are no reports describing RMS arising from a CM at a young age. We describe the first case of this kind that underwent robotic excision and hepaticojejunostomy.

Methods:

Patient's clinical notes and investigations were reviewed. Literature search of MEDLINE, Web of science and CENTRAL was performed.

Results:

A 3yr old patient presented with obstructive jaundice and fever. Ultrasound and MRCP appearances suggested type 4 CM; with ectatic intrahepatic ducts. There were unusual CM features, with the presence of sludge in the upper parts of the extra-hepatic biliary system, unresponsiveness to ursodeoxycholic acid and a non-distended gallbladder.

Patient was scheduled for robotic excision and hepaticojejunostomy. Intraoperative frozen sections confirmed malignancy. Excision was performed robotically.

Histology confirmed embryonal botryoid RMS near the origin of the cystic duct. Patient received further adjuvant chemotherapy and proton beam therapy as per oncological protocol. The patient remains recurrence free 7 years later.

Conclusions:

To authors best knowledge, this represents the first case report of a robotic excision of biliary tract RMS arising in a CM. It demonstrates the importance of high index of suspicion in the diagnosis of malignancy in association with CM, especially in the presence of unusual features. Minimal invasive approach can safely be considered in selected oncological cases.

G14 UNUSUAL COMPLICATION FOLLOWING MINIMAL ACCESS CHOLEDOCHAL EXCISION AND HEPATICO-JEJUNOSTOMY

Saimit Benkalkar, Matcovici Melania, Dawrant Michael, Alizai Naved. Leeds Children's Hospital, Leeds

Aim

Over the last 15yrs choledochal anomalies presenting at senior author's unit have been managed with Robotic assisted excision and Hepatico-jejunostomy. A variety of complications can be encountered in the post-operative period. We present a case of type 1c choledochal, with an unusual complication; a decade after uncomplicated post-operative period.

Methods

Patient clinical records were reviewed. A thorough literature review was performed.

Results

Patient underwent robotic choledochal excision and hepatico-jejunostomy uneventfully at 6yrs of age and remained satisfactory symptomatically, biochemically and on annual radiological examination for 9 years, at

which stage she experienced post-prandial epigastric pain with raised liver function tests. Ultrasound and MRCP demonstrated marked intrahepatic biliary dilatation, strictures and stones. Percutaneous transhepatic cholangiography and balloon calibration of hepatico-jejunostomy did not suggest narrowing of the anastomosis. Patient underwent spyglass stricturoplasty & gallstone removal.

Following further episode of cholangitis a barium study demonstrated jejuno-hepatic reflux. Patient underwent roux loop lengthening and roux loop endoscopy, which again, did not suggest narrowing of the anastomosis.

Symptoms persisted and she represented with cholangitis and stone formation. After a repeat MRCP, the decision was made to revise the hepato-jejunostomy & create an anti-reflux valve. Liver biopsy was performed, which suggested biliopathy.

Literature review has not found a case where a type 1 choledochal, after an uneventful hepatico-jejunostomy and no anastomotic stricture had caused multiple unrelenting intrahepatic strictures.

Conclusions

This case highlights the importance of long term follow up of Choledochal patients. It is not clear if biliopathy is the cause or the effect.

14:00-14:55 Virtual Papers and Videos Session

V1 EXPLORING UNIPORTAL VIDEO-ASSISTED THORACOSCOPY IN PAEDIATRIC ONCOLOGY: EARLY INSIGHTS AND SURGICAL RESULTS (VIRTUAL)

Mário Rui Correia, Carvalho Catarina; Barros Ana; Cagigal Jorge; Morgado Hélder; Carvalho Fátima; Paupério Gonçalo. Centro Hospitalar Universitário de Santo António

Aims

Although becoming a well-recognised approach for adult patients, extremely limited literature exists concerning uniportal video-assisted thoracoscopy (U-VATS) among paediatric cases. This study aims to present our initial experience with this approach, since a interinstitutional protocol was signed between a Thoracic and a Paediatric Surgery Department to treat oncological paediatric patients.

Methods

Perioperative parameters and surgical outcomes for all paediatric oncology patients who underwent a U-VATS surgery in our department from March 2020 to December 2022.

Results

Ten patients underwent U-VATS operation. There were 3 aspergilloma resection, 3 mediastinal biopsies for lymphopoietic tumours and 3 metastasectomies – one previously marked by interventional radiology. One paraganglioma case was converted to open, due to tumour location in the left atrium. The median age was 15.5 years old (3-17). Median operating time was 55 minutes. Thirty-day mortality rate was zero, and median length of stay was 2.5 days. There were no complications to report. With this early experience we value its advantage to allow palpation of thoracic masses when compared to traditional thoracoscopy.

Conclusion

The application of this technique in paediatric population is not widespread and reports in literature are still limited. However, we emphasize in the reproducibility and safety of single incision VATS, already encompassing a range of diverse procedures.

V2 A COMPARATIVE STUDY BETWEEN TWO TECHNIQUES OF LAPAROSCOPIC ORCHIOPEXY FOR INTRA-ABDOMINAL TESTIS (VIRTUAL)

Muhammad Azhar. Shazia Jalil; Fazal Nouman Wahid; Ghaida Alabidi; Omar Bajaber; Parameaswari Jaganathan; Saad Al Hamidi; Khalid Alfifi; Tarek Harb; Abdelbasit E.Ali; Mishraz Sheikh. King Saud Medical City, Riyadh, Saudi Arabia

Objective:

The study aims to compare outcomes between the two techniques Fowler Stephens Laparoscopic orchiopexy (FSLO) and laparoscopic traction (Shehata) orchiopexy and compare the impact of age at orchiopexy on the post-operative risk of testicular atrophy, and mal-positioning.

Methods:

We conducted a retrospective analysis of the clinical data of patients who underwent the two-stage Shehata technique and FSLO for intra-abdominal testis from August 2016 to September 2019. Baseline characteristics as well as post-operative outcomes were recorded for analysis.

Results:

Twenty patients were treated by two-stage laparoscopic orchiopexy including one case of bilateral intra-abdominal testes in each group. Eleven patients were treated by laparoscopic traction orchidopexy and nine were by FSLO. Our primary outcome testicular atrophy was observed in 30% (3/10) who underwent FSLO whereas no testicular atrophy was seen in patients who underwent the Shehata group ($p=0.011$). In the Shehata group, 75% (9/12) of the testis were found in the normal scrotal position whereas 60% (6/10) achieved scrotal position in the FSLO group ($p=0.001$). 75% of the testis were found to have an appropriate size in the Shehata group, whereas only 30% of the testis had normal size in the FSLO group ($p=0.001$). In the FSLO group, the scrotal position was more successfully achieved in the older age group ($p=0.006$)

Conclusion:

We conclude that the laparoscopic traction technique is superior to FSLO in preserving vascularity and achieving the scrotal position of the testis in children under four years of age. Whereas FSLO has better results in older age groups.

V5 LAPAROSCOPIC RECTOPEXY IS A SAFE AND EFFECTIVE PROCEDURE IN THE TREATMENT OF PAEDIATRIC RECTAL PROLAPSE (VIRTUAL)

Shehryer Naqvi, Simon Blackburn, Joe Curry. Great Ormond Street Hospital, London

Aims

1. To present our experience in operative management of paediatric rectal prolapse (PRP).
2. To determine the safety and efficacy of laparoscopic rectopexy (LR).

The primary outcome was the rate of recurrence.

Methods

We performed a retrospective review of patients with PRP treated with LR between July 2015 and April 2023. We collected demographic data; data on co-morbidities; management prior to the decision to operate; pre-operative investigations; length of stay (days); presence of recurrence; duration of follow up (months). Results are presented as median (range)

Results

Eight patients (7 male (88%)) underwent LR for PRP. Age at procedure was 12 years (2-16). One patient (13%) had a recurrence. Pre-operatively, sweat test was performed in 5 patients (63%); MRI pelvis in 4 patients (50%); anorectal manometry in 3 patients (38%). All patients received laxatives prior to the decision to manage operatively. One (13%) patient had 2 treatments with oily phenol; 1 (13%) had one dose of botulinum toxin; 2 patients (25%) underwent biofeedback training. Intra-operatively 3 non-absorbable, monofilament sutures were used in 5 patients (63%) and 2 sutures in the remaining patients. In the 1 re-do procedure absorbable, monofilament suture was used. Post-operative length of stay was 2 days (1-3). The 1 recurrence was managed with re-do LR. They have had no further recurrence. Follow up was for 11 months (1-28)

Conclusions

LR is safe and effective for the operative management of PRP. Recurrence can be managed using the same procedure

G1 THE ADVANTAGE OF LAPAROSCOPY FOR UNILATERAL INGUINAL HERNIA REPAIR IN INFANTS: A 7-YEAR RETROSPECTIVE ANALYSIS FROM NORTHEAST ENGLAND

Vinayak Prakash Thattaruparambil, Shivani Kuttuva, Maheen Qazi, Milan Gopal. Great North Children's Hospital, Newcastle

Background and Aim

Detection and treatment of a contralateral open deep ring, therefore preventing the occurrence of a metachronous hernia (MH), is the main advantage of a laparoscopic approach for unilateral inguinal hernia (UIH). We sought to find the incidence of MH in our centre and to identify risk factors for their development.

Methods:

Data on infants (age <1 year) operated for UIH between 2016 and 2022 were retrospectively gathered. Operative approach, status of contralateral ring at laparoscopy and incidence of MH were noted. Follow up was a minimum of 1yr. During laparoscopy, any open contralateral ring was closed. Children >1-year, bilateral hernias at presentation and recurrences were excluded from the study.

Results:

733 infants were included. 665 (90.7%) had an open repair and 68 (9.3%) laparoscopic. 41/68 (60%) laparoscopic cases were noted to have an open contralateral ring, that was then closed. The incidence of MH was 9.8% (66/665) in the open group whereas no patient in the laparoscopic group had a MH. The number needed to treat to prevent MH is 10. There were no adverse events noted after closing an asymptomatic contralateral open ring. Significant risk factors for MH included ex premature children with a history of oxygen requirement that were operated on as an emergency.

Conclusion:

Laparoscopic repair for children presenting with UIH prevents the occurrence of MH, particularly in those with certain risk factors.

V6 (FTF) PROCTOCOLECTOMY AND ILEAL J POUCH ANASTOMOSIS FOR FAMILIAL ADENOMATOUS POLYPOSIS IN A PAEDIATRIC PATIENT (VIDEO)

Annita Budzanowski. Carlo Manzo; Dylan Wills; Warren Hyer; Alexander Macdonald; Valerio Celentano; Muhammad Choudhry. Chelsea and Westminster Hospital, London

This video demonstrates a pan-proctocolectomy and Ileal-J pouch anal anastomosis for familial adenomatous polyposis (FAP) in a 9 year old girl, which was done jointly by the adult and paediatric colorectal team. She has a family history of FAP who under surveillance was found to have more than 100 adenomas up to the anorectal margin. The national multidisciplinary meeting (MDT) recommended to proceed with a laparoscopic proctocolectomy and J-pouch reconstruction. The aims were to perform the procedure jointly by the adult and paediatric surgery team in a high volume centre, cover the pouch with a temporary ileostomy and do a hand sawn anastomosis. Using a 4-port technique, the colon was mobilised and the proctectomy performed. In lithotomy position the incision was made on the dentate line and stay stitches placed circumferentially to provide equal retraction. After a circular dissection of 5 cm of mucosal cuff, a full thickness dissection of the rectum was performed and the specimen retrieved trans-anally. The terminal ileum was retrieved, two limbs of 15cm ileum were measured and a stapler deployed to create the pouch. A hand-sawn ileo-anal anastomosis with 16-point fixation was performed and an on table pouchoscopy. Finally, a terminal loop ileostomy was created. In conclusion a referral to a high-volume centre with adequate expertise is recommended to facilitate a safe combined colectomy and ileo-anal pouch surgery in paediatric patients. A joint paediatric- adult MDT approach is essential for any decision making, providing expertise-sharing cornerstone of the best outcome for the patient.

V7 (FTF) MANEUVERS IN INTRACORPOREAL SUTURING

Tharanga Gamage, Abraham Cherian. Great Ormond Street Hospital, London

Operative video presentation

Despite recent rapid advancements in laparoscopic surgery, complexity in intracorporeal suturing poses a hurdle for surgical trainees to adopt a wide range of laparoscopic procedures.

We demonstrate a variety of maneuvers in intracorporeal suturing using an operative video of laparoscopic pyeloplasty.

Loading the needle

1. We demonstrate the technique of transferring the needle between dominant and non-dominant laparoscopic instruments, until the needle is correctly loaded and oriented on to the needle holder.
2. An alternative technique of loading the needle by picking it up with the needle holder when the needle is lying on soft tissue is demonstrated next.
3. We demonstrate the technique of manipulating the needle to achieve a functional position by using the non-dominant instrument to gently push the needle while loosely grasping it with the needle holder.
4. We emphasize the importance of maintaining the sharp tip of the needle by avoiding catching it with instruments.

Needle tip for tissue handling

5. The video displays the technique of using the tip of the needle to engage and expose tissue during laparoscopic suturing for effective and safe tissue handling

The "slip knot" alternative – the "three throw" knot

6. Lastly, the technique of tension suturing as an alternative to the slip knot is demonstrated.

Although unquantified, they are simple maneuvers that subjectively improve ergonomics, reduce operative time, frustration, and fatigue; addressing what trainee surgeons encounter in the early years of laparoscopic training.

X1 (FTF) ROBOTIC REIMPLANTATION: TIPS & TRICKS

Marie-Klaire Farrugia. Chelsea and Westminster Hospital, London